



ELSEVIER

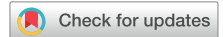Contents lists available at ScienceDirect

The Journal of Arthroplasty

journal homepage: www.arthroplastyjournal.org

Primary Hip

Mid-Term Results After 517 Primary Total Hip Arthroplasties With a Shortened and Shoulderless Double-Taper Press-Fit Stem: High Rates of Aseptic Loosening

Moritz Wagner, MD^{a,*}, Hannes Schönthaler^a, Franz Endstrasser, MD^a, Dietmar Dammerer, MD, PhD^b, Paul Nardelli, MD^b, Alexander Brunner, MD^a^a Department of Orthopaedics and Traumatology, Bezirkskrankenhaus, St. Johann, Tyrol, Austria^b Department of Orthopaedics and Traumatology, Medical University Innsbruck, Innsbruck, Tyrol, Austria

ARTICLE INFO

Article history:

Received 30 June 2021

Received in revised form

30 August 2021

Accepted 1 September 2021

Available online 17 September 2021

Keywords:

THA

stem

shoulderless

migration

loosening

WOMAC

ABSTRACT

Background: Shorter double-taper stems with reduced lateral shoulders facilitate implantation via the muscle-sparing direct anterior approach and are becoming increasingly popular. We observed an unusually high number of cases of aseptic loosening with the use of a modified stem. Therefore, the aim of this prospective single-center study was to assess safety and efficacy of this cementless stem.

Methods: A total of 486 consecutive patients receiving 517 primary total hip arthroplasties using the MonoconMIS stem were prospectively followed up for a mean period of 5.29 years (standard deviation [SD], 1.47). Surgical and clinical data, complications, and revision surgeries were analyzed. The Western Ontario and McMaster Universities Arthritis Index (WOMAC) score was recorded before surgery and at one year and five years after surgery.

Results: The overall 5-year implant survival rate was 95.2%. The individual component survival rates were 96.1% for the stem, 99.4% for the acetabular cup, and 99.0% for the isolated mobile component exchange. The most common reasons for revision were periprosthetic fracture (1.5%), aseptic stem loosening (1.4%), and infection (1.0%). The WOMAC score improved significantly from 49.57 (SD, 21.42) at baseline to 13.33 (SD, 16.47) at one year and 9.84 (SD, 14.45) at five years after surgery. Aseptic stem loosening occurred only in patients with Dorr type A proximal femur morphology.

Conclusion: The evaluated femoral stem is associated with revision rates higher than what has been reported for other implants. The WOMAC scores suggest adequate efficacy. Our data do not support the use of the MonoconMIS for primary total hip arthroplasty in patients with Dorr type A proximal femur morphology.

© 2021 Elsevier Inc. All rights reserved.

Total hip arthroplasty (THA) with cementless implant fixation has become very popular since its introduction in the 1960s [1,2], and a variety of implant designs have been introduced over the last few decades, most of which have shown favorable clinical results and good long-term survival [1–4]. In our department, we have used the Monocon straight stem (Falcon Medical, Austria) along with the Siocon press-fit cup (Falcon Medical, Austria; Fig. 1) as the standard implant for THA from 2005 onward [5]. Both implants have highly satisfactory long-term survival rates, comparable with other well-performing implants [6–9]. However, with increasing

numbers of surgeons changing their standard approaches from posterior and lateral to anterolateral and direct anterior approach (DAA), it became necessary to adopt new implant designs to enable easier introduction of the stem into the femoral canal. We therefore began using the MonoconMIS stem (Falcon Medical, Austria; Fig. 2) as the standard implant for primary THA from 2014 onward. The MonoconMIS stem, introduced in 2013, is a modified version of the straight Monocon stem (Fig. 3), the main differences being the shoulderless design and the shorter total length.

Since switching to the modified stem, we have observed an unusually high number of cases of aseptic stem loosening, which was rare when we were using the previous model. The purpose of this prospective clinical single-center study was to evaluate the outcomes of primary THA performed using the MonoconMIS stem and the Siocon press-fit cup. We hypothesized that the rates of

No author associated with this paper has any potential or pertinent conflicts which may be perceived to have impending conflict with this work.

* Address correspondence to: Moritz Wagner, MD, Bezirkskrankenhaus St. Johann i.T., Bahnhofstrasse 14, 6380 St. Johann, Tyrol, Austria.

<https://doi.org/10.1016/j.arth.2021.09.004>

0883-5403/© 2021 Elsevier Inc. All rights reserved.

early aseptic loosening would be higher with the modified stem than with conventional stems.

Patients and Methods

Between 2014 and 2016, a total of 517 hips (264 right, 253 left, and 62 bilateral) in 486 patients (287 women and 199 men) were treated by primary THA with the MonoconMIS stem and the Siocon cup. All surgeries were performed at the same center, although by different arthroplasty surgeons. After surgery, patients were followed up for a mean period of 5.3 years (standard deviation [SD], 1.47; range, 0.01–5.99). Demographic characteristics of patients, indication for surgery, body mass index (BMI), type of surgical approach, operation time, types and sizes of implants, length of hospital stay, intraoperative and postoperative complications, and revision surgeries, if any, were documented in our institution's medical database.

All patients were asked to complete the self-administered Western Ontario and McMaster Universities Arthritis Index (WOMAC) before surgery and at one year and five years after surgery [10]. As per the recommendations of Yeo et al, a difference of more than ten points in the WOMAC score between two consecutive time points was considered a clinically important difference. Patients with deterioration of more than ten points compared with the previous evaluation were invited for clinical and radiological follow-up.

We matched our data with the Tyrolean joint replacement registry (Austria) to detect revision surgeries performed in other hospitals. Surgical reports of all revision arthroplasties were obtained. The exchanged components were documented. Reasons for revision were grouped into categories.

The MonoconMIS stem is a modified version of a double-taper straight stem. It is a nonmodular cementless double-tapered stem, classified as “anatomic” according to Janssen et al [11] and as “type 2” according to Khanuja et al [12]. It has a reduced lateral bevel (shoulderless design) that facilitates its introduction into the femoral canal through direct anterior and anterolateral approaches and minimizes the risk of iatrogenic periprosthetic fractures (Fig. 2). The stem is designed for dia-metaphyseal fixation and has a shorter total length than its predecessor, the Monocon stem (Fig. 3).




Fig. 1. The Siocon press-fit hemispherical cup with a fourth-generation ceramic liner.



Fig. 2. The evaluated MonoconMIS press-fit stem with a reduced lateral shoulder and shorter overall length.

This stem comes in two variants, with caput-collum-diaphyseal angles of 125° or 131° and different neck lengths. It is available in 12 stem sizes; the smallest (size 1) has a length of 116 mm, and the largest (size 12) has a length of 155 mm (Figs. 1 and 3). The 12/14 mm cone is designed as per the specifications for ceramic heads, but can also be used with metal heads of the same cone specification.

The Siocon cup is a cementless spherical press-fit cup for use with metal-backed liners [5]. The liners used in this study were




Fig. 3. The predecessor Monocon press-fit stem with greater total length and a lateral shoulder.

either fourth-generation ceramic (BioRxDelta, CeramTec; Fig. 1) or highly cross-linked polyethylene, all preassembled with a titanium metal shell (ie, metal-backed; Fig. 1). Ceramic liners were used in 332 of 517 (64.2%) hips and highly cross-linked polyethylene liners, in 185 of 517 (35.8%) hips. While 36-mm heads were used in 326 of 517 (63.1%) hips, 32-mm heads were used in 187 of 517 (36.2%) hips, and 28-mm heads were used in 4 of 517 (0.8%) hips.

This study was conducted in accordance with the declaration of Helsinki (Medical University Innsbruck, Austria; Process No: 1224/2020). Independent ethics committee approval was obtained for performing this study, and written informed consent was obtained from all patients. None of the authors were involved in primary patient care.

Statistical Analysis

Implant survival was recorded, and Kaplan–Meier survival analysis was performed. All parameters were checked for normal distribution. Pearson correlation was used to examine the relationship between numerical variables. One-way analysis of variance with Tukey post hoc testing was used to compare mean values between groups. The chi-square test was used for comparison of categorical data. The denominator for all reported percentages was the number of hips, not the number of patients. Statistical significance was at $P \leq .05$ for all tests.

Results

The mean age at the time of arthroplasty was 66.9 (SD, 11.1; range, 33 to 93) years. Primary hip osteoarthritis was the most common indication for surgery (92.6%), followed by aseptic necrosis of the femoral head (2.7%), post-traumatic osteoarthritis (2.3%), developmental dysplasia (2.1%), and other conditions (0.2%). Implant survival time and WOMAC scores were not significantly different between patients with different diagnoses.

The mean BMI was 27.6 kg/m² (SD, 5.4; range, 18.2 to 65.1). Patients with a higher BMI had significantly worse WOMAC scores at one year ($r = 0.196$, $P < .001$) but not at five years ($r = 0.076$; $P = .25$) after surgery.

The anterolateral approach was most commonly used (340/517, 65.8%), followed by the posterolateral approach (113/517, 21.9%) and DAA (64/517, 12.4%). Patient-reported outcomes (WOMAC score) at one year and five years after surgery were comparable between patients treated by different surgical approaches. Overall implant survival time was significantly shorter in patients receiving joint replacement via the DAA than that in patients receiving joint replacement via the other approaches (4.78 years vs 5.29 years; $P = .012$).

The mean operation time was 59.28 minutes (SD, 15.92; range, 31 to 139). Operation time was positively correlated with BMI ($r = .199$; $P < .001$) and age ($r = .214$; $P < .001$). The mean length of hospital stay was 8.51 days (SD, 3.19; range, 5 to 25). Patients with longer hospital stay had shorter implant survival ($r = -.223$; $P < .001$).

Intraoperative complications occurred in 14 of 517 (2.71%) cases; in 4 (0.77%) cases, an iatrogenic periprosthetic fracture occurred, and in 1 of those cases, an osteosynthesis with cerclage wires was required. In ten (1.93%) cases, severe acetabular osteolysis complicated cup placement, and in four of those cases, an autologous bone grafting was necessary.

Postoperative complications occurred in 49 of 517 (9.5%) cases; these included medical complications (deep venous thromboembolism, pulmonary embolism, stroke, and postoperative delirium) in 24 (4.6%) cases, need for blood transfusion in 14 (2.7%) cases, wound-healing disorders (not requiring reoperation) in five (1.0%)

Table 1
Overall WOMAC Scores and Subscale Scores at Different Time Points.

Time Point	Subgroup	Mean	SD
Before surgery (n = 369)	Pain	47.9	22.9
	Stiffness	50.0	27.1
	Function	50.8	22.6
	Total	49.6	21.4
At 1 y after surgery (n = 443)	Pain	10.3	15.8
	Stiffness	16.1	19.9
	Function	13.6	18.0
	Total	13.3	16.5
At 5 y after surgery (n = 312)	Pain	7.4	13.5
	Stiffness	12.6	17.9
	Function	9.7	15.0
	Total	9.8	14.5

WOMAC, Western Ontario and McMaster Universities Arthritis Index.

cases, neurological impairment, with different degrees of paresis, in three (0.6%) cases, and audible squeaking in the hip (many years after implantation) in three (0.6%) cases. All patients were treated conservatively. Patients who developed complications had significantly worse overall WOMAC scores at one year (19.75 vs 12.66; $P = .009$) and five years (18.15 vs 9.27; $P = .008$) after surgery than patients without complications.

The numbers and overall score of WOMAC questionnaires can be found in Table 1 (Table 1). In 38 of 517 (7.3%) cases, the overall WOMAC score deteriorated by more than ten points at final follow-up compared with their score at one year after surgery. These patients were contacted by phone and invited for detailed clinical follow-up. While 14 patients could not be contacted, six patients were afraid to visit the outpatient clinic because of the COVID-19 pandemic. Among the patients who accepted clinical follow-up, no specific reason for deterioration of the WOMAC score could be identified in five patients. In the remaining patients, the causes for worsening of the WOMAC score included gait affected by neurological conditions unrelated to the surgery (five patients), Trendelenburg gait due to insufficiency of the hip abductor muscles (four patients), late joint dislocations that could be treated conservatively (two patients), and aseptic loosening in more than three Grün zones (two patients) [13].

The overall 5-year implant survival rate was 95.2%. The survival rate was 96.1% for the stem, 99.0% for the isolated mobile component exchange, and 99.4% for the cup (Fig. 4). Risk stratification for component failure showed that aseptic component loosening occurred in younger patients (63.0 years, SD 8.85) and periprosthetic fracture in older patients (77.0 years, SD 9.08; $P = .037$). Aseptic stem loosening occurred in seven cases, all with 36-mm heads ($P = .012$). All seven cases of aseptic stem loosening were in men, whereas seven of eight cases of periprosthetic fracture were in women ($P = .006$). Table 2 lists the reasons for revision.

Radiological analysis of the cases with aseptic loosening of the stem showed cortical thickening around the tip of the stem in Grün zones 3, 4, and 5 and osteolysis around the body of the stem in Grün zones 1, 2, 6, and 7 [7,12]. In all cases of aseptic loosening, the proximal femur was classified as Dorr type A [14]. Stem migration measurement showed mean stem subsidence of 4.8 mm (SD, 2.73; range, 0 to 9). Radiologic analysis of the other cases undergoing revision arthroplasties revealed no abnormalities.

Discussion

The findings of this study confirmed our hypothesis that aseptic loosening is more common with the MonoconMIS stem than with other standard implants [15–17]. Siocon cup survival was unaffected by its use in combination with this stem system [5].

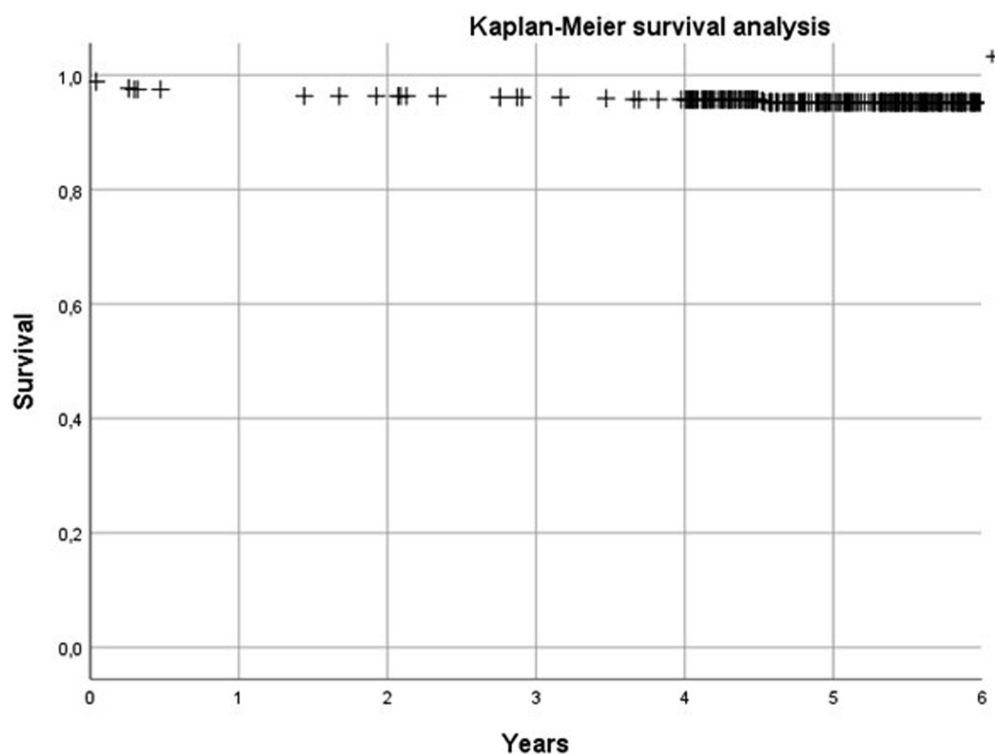


Fig. 4. Kaplan–Meier analysis of implant survival.

Radiological analysis revealed that cases of early loosening occurred in patients with narrow diaphyseal canals and wide meta-epiphyseal areas (Dorr type A). Because the MonoconMIS stem is shorter and has thicker tips than the previous model, there may be greater diaphyseal stress, especially in Dorr type A proximal femurs (Fig. 5). In such cases, metaphyseal fixation may be insufficient. This is consistent with the findings of Park et al who showed that double-taper wedge stems have increased risk of failure in Dorr type A femurs [18]. Overall, we assume that the high revision rate observed in this trial may be the result of a mismatch between patient anatomy and stem design, and we emphasize the importance of preoperative templating and planning [11]. Furthermore, in view of the lower BMI

in our patient cohort than in cohorts reported from other regions, we speculate that our patients had a higher level of physical activity [19]. A higher level of physical activity and strain may be associated with a higher prevalence of Dorr A proximal femur anatomy, in accordance with Wolff's law [20]. However, we are unaware; this has yet to be scientifically demonstrated.

In our cohort, most of implantations were performed using an anterolateral approach; the DAA was less often used. Nevertheless, most cases of stem loosening and periprosthetic fractures occurred in patients treated with the DAA [11,12]. This may have also been due to a learning curve of arthroplasty surgeons in our department who were switching from their standard approach to the DAA [21].

Table 2

Reasons Leading to Revision With Mean Age, Sex, BMI, and Length of Procedure.

Reason Leading to Revision of 517 THAs	Age (Years)	Sex (M/F Ratio)	BMI (kg/m ²)	Length of Procedure (min)
Periprosthetic femoral fracture (n = 8, 1.5%)				
Mean	77.0	0.13	30.0	61.6
SD	9.1		13.8	15.8
Aseptic stem loosening (n = 7, 1.4%)				
Mean	63.0	1.00	27.2	70.3
SD	8.9		3.4	15.2
Periprosthetic infection (n = 5, 1.0%)				
Mean	70.4	0.80	31.0	58.4
SD	9.9		5.7	22.0
Aseptic cup loosening (n = 2, 0.4%)				
Mean	56.0	-	19.5	100.5
SD	4.2		-	41.7
Liner malpositioning (n = 2, 0.4%)				
Mean	73.0	0.50	-	45.0
Dislocation (n = 1, 0.2%)				
Mean	73.0	-	34.2	68.0
Total revisions (n = 25, 4.8%)				
Mean	69.6	0.52	28.6	65.4
SD	10.4		7.1	21.1

BMI, body mass index; THA, total hip arthroplasty; SD, standard deviation.

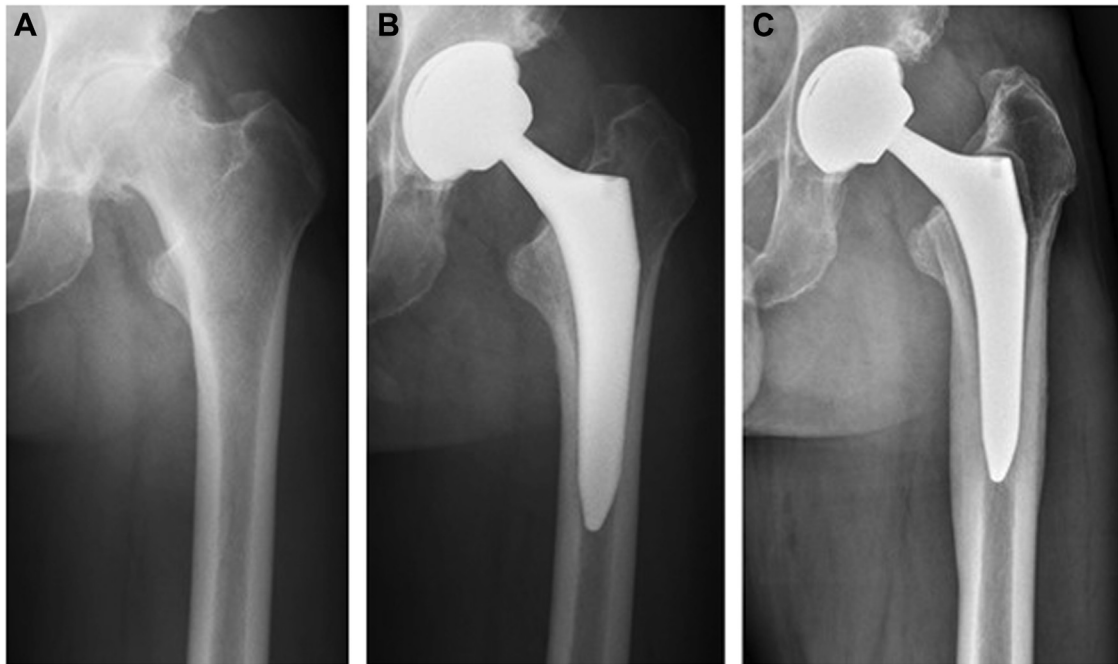


Fig. 5. Radiographs of a patient obtained before surgery (A; Dorr type A femur), at 6 weeks after surgery (B) without symptoms, and at 3 years after surgery (C) with aseptic stem loosening before revision surgery.

Our study found significant sex differences. As mentioned before, the vast majority of periprosthetic fractures were in women. The increased risk for periprosthetic fracture in women undergoing uncemented THA has been previously demonstrated by large-scale registry analyses [22].

The United Kingdom National Institute for Health and Care Excellence has recently published its revised benchmark recommending ten-year implant survival rates of >95% [23]. Numerous implants have demonstrated even higher survival rates and are therefore considered safe for primary THA [24]. The evaluated acetabular cup and metal-backed liner system showed excellent clinical and patient-reported outcomes and high implant survival rates and can therefore be used without concern for primary THA. However, the evaluated stem showed higher rates of failure than other available implants, although the failure rate at five years was below the recommended threshold.

This study assessed clinical and patient-reported outcomes of an implant that has not been investigated before. The strengths of this study are its prospective nature, the use of patient-reported outcome measurement (WOMAC), and the matching of data with a joint replacement registry to identify all revision surgeries.

The primary limitation of this study is the relatively short follow-up period of five years. However, because we suspected higher rates of aseptic loosening with the MonoconMIS stem than with the previously used implant, a longer follow-up would not have been ethical. Hence, the MonoconMIS stem is no longer used in our institution. A second limitation is the relatively small sample size.

Conclusion

The shortened length and reduced shoulder of the double-taper MonoconMIS stem are associated with high rates of aseptic loosening in Dorr type A proximal femurs. The overall revision rates are higher than what has been reported for other implants. The WOMAC scores suggest adequate efficacy in patients not needing

revision surgery. Overall, the data of this study do not support the use of this stem as the standard implant for primary THA in patients with Dorr type A proximal femur morphology.

References

- [1] Kumar A, Bloch BV, Esler C. Trends in total hip arthroplasty in young patients - results from a regional register. *Hip Int* 2017;27:443–8.
- [2] Sheridan GA, Kelly RM, McDonnell SM, Walsh F, O'Byrne JM, Kenny PJ. Primary total hip arthroplasty: registry data for fixation methods and bearing options at a minimum of 10 years. *Ir J Med Sci* 2019;188:873–7.
- [3] Gkagkalis G, Goetti P, Mai S, Meinecke I, Helmy N, Bosson D, et al. Cementless short-stem total hip arthroplasty in the elderly patient - is it a safe option?: a prospective multicentre observational study. *BMC Geriatr* 2019;19:112.
- [4] Kutzner KP, Donner S, Loweg L, Rehbein P, Dargel J, Drees P, et al. Mid-term results of a new-generation calcar-guided short stem in THA: clinical and radiological 5-year follow-up of 216 cases. *J Orthop Traumatol* 2019;20:31.
- [5] Wagner M, Schönthaler H, Endstrasser F, Neururer S, Leitner H, Brunner A. Survivorship of Ceramic on Ceramic total hip arthroplasty with metal-backed acetabular liners at ten years. *J Arthroplasty* 2021 [Epub ahead of print].
- [6] Chatelet JC, Ait-Si-Selmi T, Machenaud A, Ramos-Pascual S, Vidalain JP, Bonnin MP, et al. Mid-term clinical and radiographic outcomes of a long cementless monobloc stem for revision total hip arthroplasty. *J Arthroplasty* 2021;36:261–7.
- [7] Peitgen DS, Innmann MM, Merle C, Gotterbarm T, Moradi B, Streit MR. Cumulative long-term incidence of postoperative periprosthetic femoral fractures using an uncemented tapered titanium hip stem: 26- to 32-year results. *J Arthroplasty* 2019;34:77–81.
- [8] Ottink K, Barnaart L, Westerbeek R, Van Kampen K, Bulstra S, Van Jonbergen HP. Survival, clinical and radiological outcome of the zweymüller SL/Bicon-Plus total hip arthroplasty: a 15-year follow-up study. *Hip Int* 2015;25:204–8.
- [9] Lehil MS, Bozic KJ. Trends in total hip arthroplasty implant utilization in the United States. *J Arthroplasty* 2014;29:27–32.
- [10] Yeo MGH, Goh GS, Chen JY, Lo NN, Yeo SJ, Liow MHL. Are Oxford hip score and Western Ontario and McMaster universities osteoarthritis index useful Predictors of clinical meaningful improvement and satisfaction after total hip arthroplasty? *J Arthroplasty* 2020;35:2458–64.
- [11] Janssen L, Wijnands KAP, Janssen D, Janssen MWHE, Morrenhof JW. Do stem design and surgical approach influence early aseptic loosening in cementless THA? *Clin Orthop Relat Res* 2018;476:1212–20.
- [12] Khanuja HS, Vakil JJ, Goddard MS, Mont MA. Cementless femoral fixation in total hip arthroplasty. *J Bone Joint Surg Am* 2011;93:500–9.

- [13] ten Broeke RHM, Hendrickx RPM, Leffers P, Jutten LMC, Geesink RGT. Randomised trial comparing bone remodelling around two uncemented stems using modified Gruen zones. *Hip Int* 2012;22:41–9.
- [14] Karayiannis PN, Cassidy RS, Hill JC, Dorr LD, Beverland DE. The relationship between canal diameter and the Dorr classification. *J Arthroplasty* 2020;35:3204–7.
- [15] Hughes RE, Batra A, Hallstrom BR. Arthroplasty registries around the world: valuable sources of hip implant revision risk data. In: *Current Reviews in Musculoskeletal Medicine*, 10. Totowa, New Jersey, USA: Humana Press Inc; 2017. p. 240–52.
- [16] Streit MR, Haeussler D, Bruckner T, Proctor T, Innmann MM, Merle C, et al. Early migration Predicts aseptic loosening of cementless femoral stems: a long-term study. *Clin Orthop Relat Res* 2016;474:1697–706.
- [17] Ferguson RJ, Palmer AJ, Taylor A, Porter ML, Malchau H, Glyn-Jones S. Hip replacement. In: *The Lancet*, 392. London, UK: Lancet Publishing Group; 2018. p. 1662–71.
- [18] Park CW, Eun HJ, Oh SH, Kim HJ, Lim SJ, Park YS. Femoral stem survivorship in Dorr type A femurs after total hip arthroplasty using a cementless tapered wedge stem: a matched comparative study with type B femurs. *J Arthroplasty* 2019;34:527–33.
- [19] Poglitsch M, Kefurt R, Mittlböck M, Bohdjalian A, Langer FX, Ludvik B, et al. Prevalence of obesity and overweight in male 18-year-olds in Austria from 2006 to 2010: an update. *Eur Surg* 2011;43:1–2.
- [20] Freiberg AH. Wolffs law and the functional pathogenesis of deformity. *Am J Med Sci* 1902;124:136–46.
- [21] Magill P, Blaney J, Hill JC, Bonnin MP, Beverland DE. Impact of a learning curve on the survivorship of 4802 cementless total hip arthroplasties. *Bone Joint J* 2016;98-B:1589–96.
- [22] Dale H, Børsheim S, Kristensen TB, Fenstad AM, Gjertsen JE, Hallan G, et al. Fixation, sex, and age: highest risk of revision for uncemented stems in elderly women — data from 66,995 primary total hip arthroplasties in the Norwegian Arthroplasty Register. *Acta Orthop* 2020;91:33–41.
- [23] Kandala NB, Connock M, Pulikottil-Jacob R, Sutcliffe P, Crowther MJ, Grove A, et al. Setting benchmark revision rates for total hip replacement: analysis of registry evidence. *BMJ* 2015;350:756–756.
- [24] Keurentjes JC, Pijls BG, Van Tol FR, Mentink JF, Mes SD, Schoones JW, et al. Which implant should we use for primary total hip replacement?: a systematic review and meta-analysis. *J Bone Joint Surg Am* 2014;96:79–97.